



# Evaluation of the Hydroethanolic Fruit Extract of *Solanum aethiopicum* (Garden Egg) on the Concentration of Reproductive Hormones, Sperm Parameters and Histology of the Testis of Male Wistar Rats.

Zabbey VZ; Adienbo OM; Ojeka SO; Dapper DV

Department of Human Physiology, Faculty of Basic Medical Sciences, College of Health Science, University of Port Harcourt, Rivers State, Nigeria.

E-mail: [zabbeyvictor@gmail.com](mailto:zabbeyvictor@gmail.com) (+2348038786260) ; [ologhaguoadienbo@gmail.com](mailto:ologhaguoadienbo@gmail.com) (+2348030953240); [sundayojeka@uniport.edu.ng](mailto:sundayojeka@uniport.edu.ng) (+2348033854898); [victordapper@uniport.edu.ng](mailto:victordapper@uniport.edu.ng) (+2348036776322)

## ARTICLE INFO

Article No.: 120321146

Type: Research

Full Text: [HTML](#), [PHP](#), [EPUB](#)

Accepted: 06/12/2021

Published: 17/12/2021

### \*Corresponding Author

Zabbey VZ

E-mail: [zabbeyvictor@gmail.com](mailto:zabbeyvictor@gmail.com)

Phone: +2348038786260

**Keywords:** Sperm, *Solanum*, Hormones, Reproductive, Fruit and Extract.

## ABSTRACT

**Background:** *Solanum aethiopicum* (eggplant) can either be eaten fresh or cooked and has a long history of consumption in West Africa. This study aimed at evaluating the effects of the hydroethanolic fruit extract of *Solanum aethiopicum* on serum reproductive hormones, sperm parameters and histology of the testis of male Wistar rats.

**Methods:** Thirty-two (32) adult male rats with average weight of 250g were used for the study. The rats were divided into four groups of 8 rats each. Group 1 served as control and was given distilled water only while the experimental groups (groups 2, 3 and 4) were given 100mg/kg, 200mg/kg and 300mg/kg respectively of *Solanum aethiopicum* fruit extract for 30 days, after which five of the experimental animals in each of the groups were sacrificed.

**Results:** The results showed a dose-dependent significant increase in the concentration of all the reproductive hormones in the test groups and a significant increase in the percentage sperm motility and viable sperm cells with respect to the control. The testis in the extract treated groups showed no tissue damage when compared with the control.

**Conclusions:** *Solanum aethiopicum* fruit can therefore boost the production of reproductive hormones, improve sperm parameters and preserve the histology of the testis in male Wistar rats.

## INTRODUCTION

Plants have been known as natural sources of fertility enhancing substances.<sup>[1]</sup> Since the dawn of human existence, infertility has remained a major medical and social preoccupation. For ages now, couples have been more concerned with conception and its difficulties.<sup>[2]</sup> Infertility is the inability to conceive after having regular unprotected sex. In African tradition, infertility is always considered to be a women's fault. However, medical evidence has shown that both genders have equal rates of infertility. Male infertility can be due to many factors including but not limited to erectile dysfunction, poor libido, psychological challenges, poor hormonal levels and poor sperm quality (low sperm count, abnormal morphology and sluggish sperm cells) due to high level of oxidative stress.

Although there are many established treatment plans for male infertility, they are either very expensive (like hormonal therapies and medications) or highly invasive like surgeries.<sup>[3]</sup> In order to tackle this disorder, there is therefore the need to resort to methods that are not only less expensive, but are also non-invasive. These methods include using plants or herbs that have medicinal values. The world health organization (WHO) has estimated that 80 percent population of some countries presently uses herbs for some aspect of primary health care. It has also been established that about 25 percent of new medicines in the United States are obtained from plants.<sup>[4]</sup> Plants with medicinal value have been extensively used to improve or regulate fertility in males. This is because medicinal plants have several beneficial effects on male fertility which include increased sexual desire (libido),<sup>[5, 6, 7]</sup> stimulatory activity of hormones,<sup>[8, 9]</sup> increased semen volume, increased sperm count and increased viability and sperm motility. The preference of herbal medicine to synthetic treatments may be because of the belief that they have less or no side effects, have high nutritional value and are relatively cheaper.<sup>[3]</sup> Most of these medicinal plants are leafy vegetables or fruits and can be easily found around us and form important components of our daily diets. A substantial number of them also contain flavonoids, saponins, tannins, alkaloids and many other constituents known to have fertility boosting effects.

The *S. aethiopicum* (garden egg) is a very common vegetable, which is mainly grown because of its leaves and fruits. The fruits and leaves of *S. aethiopicum*

can be eaten in so many forms such as fresh state, steamed, juiced, pickled or boiled. The leaves can also be used in preparing stews or soups

This study was therefore aimed at establishing the effect of the consumption of *Solanium aethiopicum* fruit on male fertility, through the evaluation of its effect on the serum concentration of the gonadotropic hormones (FSH and LH), Testosterone, Prolactin, sperm parameters and the histology of the testis.

## MATERIALS AND METHODS

A total of 32 adult male Wistar rats with average weight of 250g were used for this study. The animals were procured from the animal care unit of Human Physiology Department of the University of Port Harcourt. These animals were housed in an environment of normal room temperature separately and were fed with standard finisher feeds (Top feed, Nigeria) and water for 14 days for acclimatization after which they were used for the experiment. The *Solanum aethiopicum* fruit used for this study was bought from a farm located at Omuokiri, Aluu in Port Harcourt, Rivers state and sent to the Department of Pharmacognosy and Phytotherapy, Faculty of Pharmaceutical Sciences of the University of Port Harcourt for identification and authentication, with voucher Number (UPHS0474). The identified fruits were washed and then ground fresh to form a paste. The maceration method was used for the extraction. About 1500 grams of the fruit of the plant after weighing were dissolved in 80% ethanol and 20% water, making up to 2000ml of Hydroethanol, for 72 hours in an extraction vessel well-kept in an air light cupboard. During the period of maceration, it was well shaken three times daily to ensure a proper absorption. The filtration was done using a glass funnel, 1000ml beaker and Whitman filter paper. The funnel was placed in the beaker. The filtrate was carefully poured into the funnel which filters through the funnel into the beaker. The extraction after filtration was dried using a rotary evaporator which separates the solvent from extract leaving it in a liquid form, which was then completely dried on a steam bath with a temperature of 45°C.

The thirty-two (32) male Wistar rats used for this study were grouped into four (4) groups with each group containing eight (8) rats as shown in the table below.

**Table 1: Experimental Design of the Study.**

S/N	GROUP NAME	SUBSTANCE ADMINISTERED
1	Group 1(Control)	Distilled water only
2	Group 2	100mg/kg BW hydro-ethanol extract of fruit of <i>S. aethiopicum</i>
3	Group 3	200mg/kg BW hydro-ethanol extract of fruit of <i>S. aethiopicum</i>
4	Group 4	300mg/kg BW hydro-ethanol extract of fruit of <i>S. aethiopicum</i>

At the expiration of 30 days of oral administration, five (5) rats from each group were sacrificed using chloroform anesthesia. The blood samples were collected for the analysis of the reproductive hormones (Follicle Stimulating Hormone, Luteinizing Hormone, Prolactin and Testosterone). Semen was also obtained from the testis for the analysis of sperm parameters (Sperm count, sperm motility, sperm viability and Sperm morphology) while the testis was harvested through abdominal incision and stained with haematoxylin and eosin stain for histopathological examination through

light microscope by the usual method described by other researchers.<sup>[10]</sup>

Ethical approval was obtained from the research Ethics committee unit of University of Port Harcourt (UPH/CEREMAD/REC/MM81/009). The statistical analysis was done using the SPSS version 20.0. The results were analysed using ANOVA with a significant difference at  $p < 0.05$ . LSD and turkeys' multiple comparison were used to test for significant differences between the experimental groups and the control. The results were presented as mean  $\pm$  SEM.

## RESULTS

**Table 2: Effects of *Solanum aethiopicum* fruit extract on Reproductive Hormones.**

Groups	FSH (miu/ml)	LH (miu/ml)	Prolactin (ng/ml)	TESTOSTERONE (ng/ml)
1 (control)	1.60 $\pm$ 0.42	1.60 $\pm$ 0.35	2.03 $\pm$ 0.23	0.83 $\pm$ 0.30
2 (100mg/kg)	3.37 $\pm$ 0.27 *	3.50 $\pm$ 0.35	2.40 $\pm$ 0.26	1.63 $\pm$ 0.18 *
3 (200mg/kg)	4.23 $\pm$ 0.15 *	4.73 $\pm$ 0.30 *	4.70 $\pm$ 0.45	1.93 $\pm$ 0.07 *
4 (300mg/kg)	4.47 $\pm$ 0.27*	4.87 $\pm$ 0.41*	4.77 $\pm$ 0.38	2.60 $\pm$ 0.25*

Data are expressed as Mean  $\pm$  SEM of 5 rats, \* represents significant differences relative to the control at  $p < 0.05$ .

**Table 3: Effects of *Solanum aethiopicum* fruit extract on Sperm parameters.**

Sperm parameters/ Groups	Normal morphology (%)	Sperm viability (%)	Sperm count (Million/ml)	Sperm motility (%)
1 (control)	93.0 $\pm$ 1.53	66.7 $\pm$ 4.41	55.0 $\pm$ 5.69	78.3 $\pm$ 10.14
2 (100mg/kg)	94.3 $\pm$ 1.20	90.0 $\pm$ 2.89*	67.3 $\pm$ 10.53	94.7 $\pm$ 2.60
3 (200mg/kg)	95.7 $\pm$ 1.76	95.0 $\pm$ 2.89*	76.3 $\pm$ 14.84.	97.7 $\pm$ 1.20*
4 (300mg/kg)	96.0 $\pm$ 3.06	97.7. $\pm$ 1.45*	80.67 $\pm$ 12.96*	98.7 $\pm$ 1.33*

Data are expressed as Mean  $\pm$  SEM of 5 rats, \* represents significant differences relative to the control at  $p < 0.05$ .



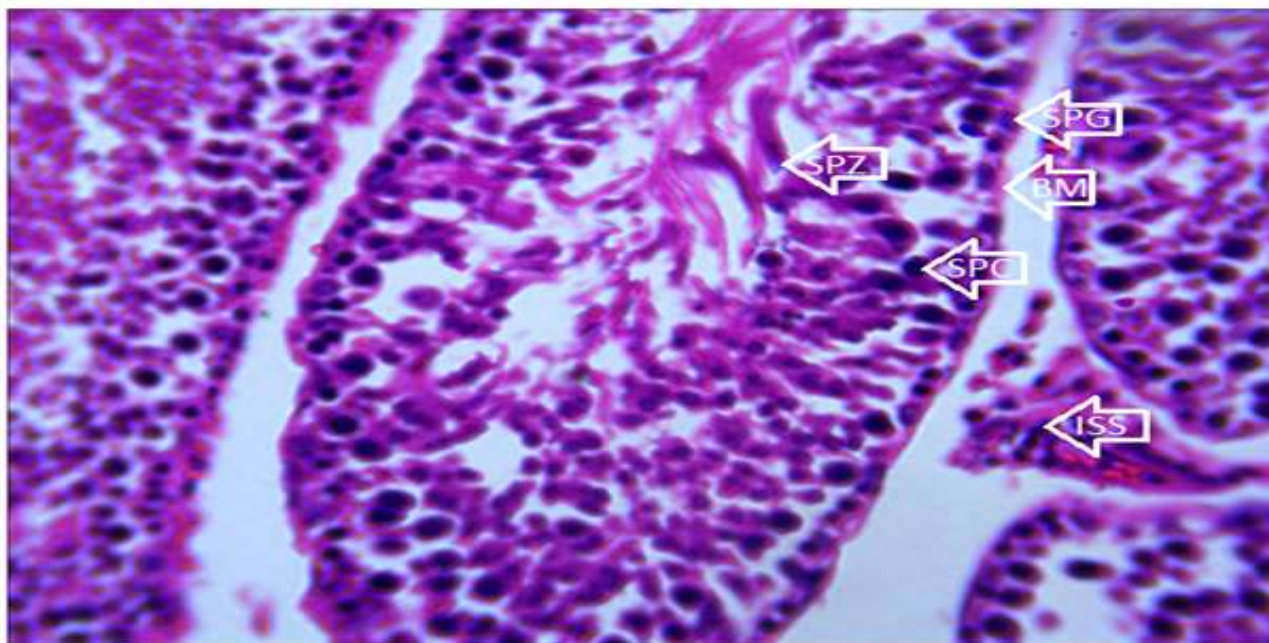


Plate 1: Photomicrograph of a section of the testis of rat of control group after 30 days period. It reveals: (a) A histologically normal testis with:  
 (a) Normally shaped seminiferous tubules containing spermatogonia (SPG), spermatocytes (SPC) and spermatozoa (SPZ), surrounded by intact basement membrane (BM).  
 (b) Interstitial spaces (ISS) containing Leydig cells  
 Stain: H & E. Magnification: X 400.

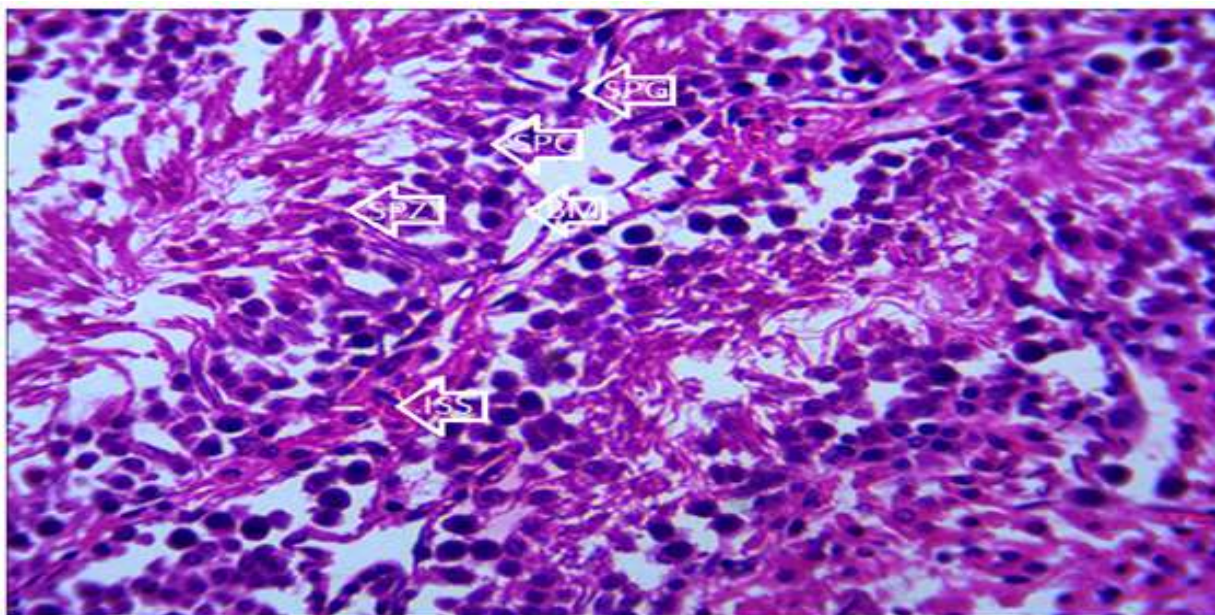


Plate 2: Photomicrograph of a section of the testis of rat of group 2 (100mg/kg of *Solanum aethiopicum* fruit extract) after 30 days period. It reveals a histologically normal testis with (a) Intact seminiferous tubules containing SPG, SPC and SPZ  
 (b) Interstitial spaces (ISS) containing Leydig cells  
 Stain: H & E. Magnification: X 400.



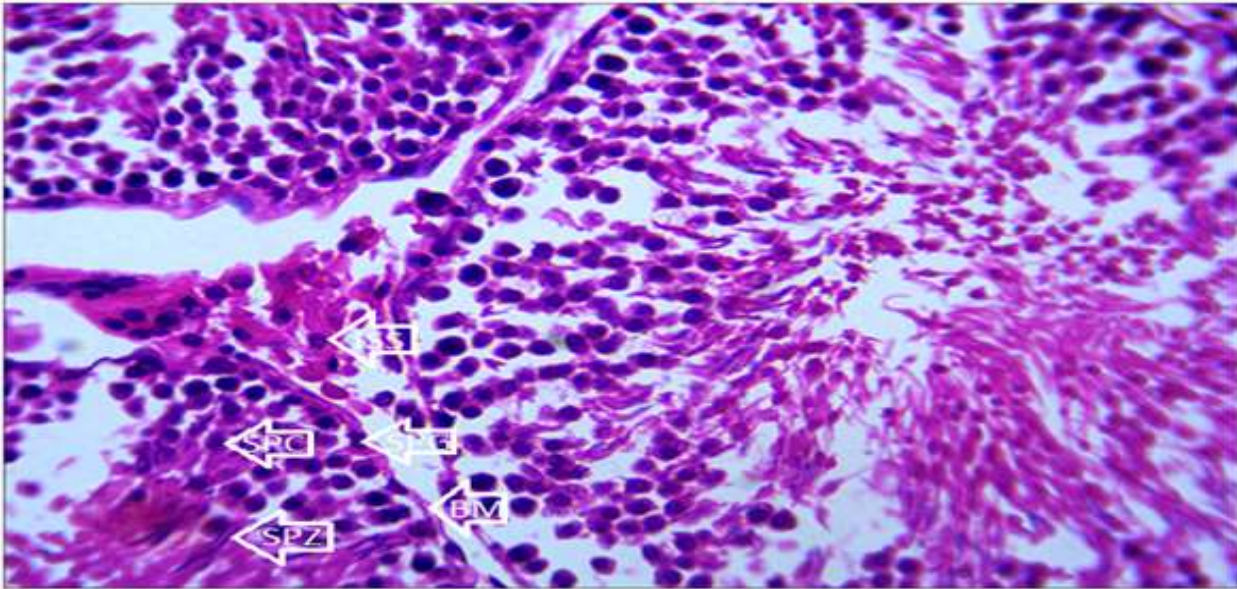


Plate 3: Photomicrograph of a section of the testis of rat of group 3 (200mg/kg of *Solanum aethiopicum* fruit extract) after 30 days period. It reveals a histologically normal testis with (a) Intact seminiferous tubules containing SPG, SPC and SPZ

(b) Interstitial spaces (ISS) containing Leydig cells

Stain: H & E. Magnification: X 400.

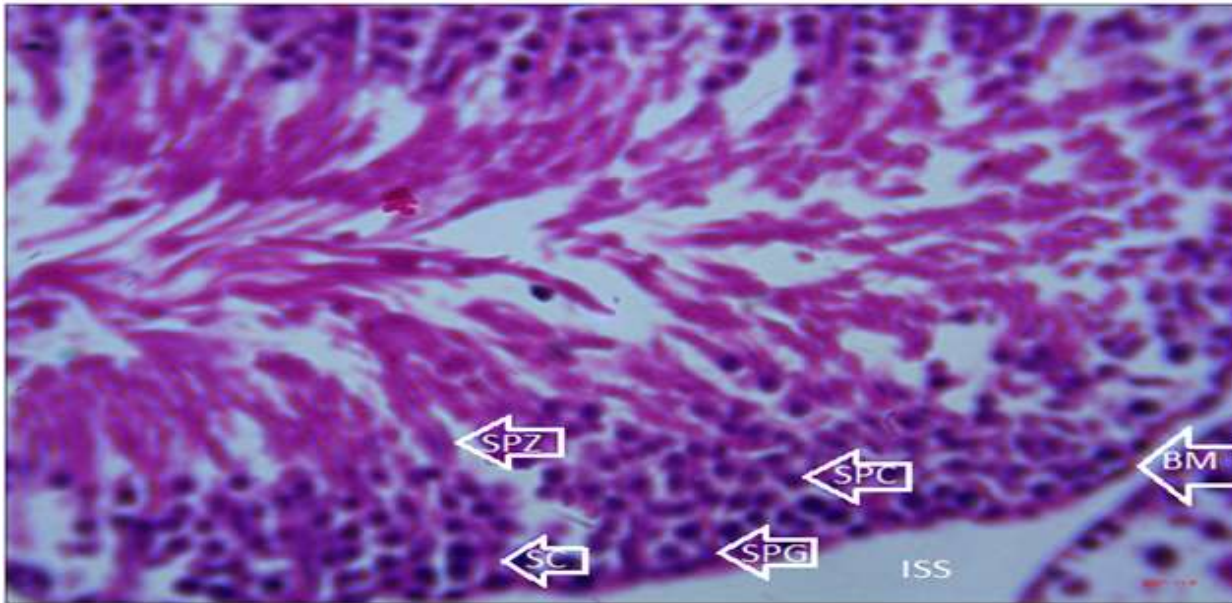


Plate 4: Photomicrograph of a section of the testis of rat of group 4 (300mg/kg of *Solanum aethiopicum* fruit extract) after 30 days period. It reveals a histologically normal testis with (a) Intact seminiferous tubules containing SPG, SPC and SPZ

(b) Interstitial spaces (ISS) containing Leydig cells

Stain: H & E. Magnification: X 400.

## DISCUSSION OF FINDINGS

### Effect of Hydroethanolic fruit extract of *S. aethiopicum* on Reproductive Hormones

The study revealed that after 30 days of administration of 100 mg/kg, 200 mg/kg and 300mg/kg of *S. aethiopicum* fruit extract, there was a statistically significant increase in the serum concentrations of Luteinizing Hormone (LH), Follicle Stimulating Hormone (FSH) and Testosterone (TET) while there was no significant change in the concentration of Prolactin (table 2). This elevated level in the concentration of the male reproductive hormones caused by the extract could be attributed to the presence of saponins which reportedly helps in improving testosterone levels and flavonoid which improves androgen levels.<sup>[11]</sup>

The principal hormones regulating fertility in males are Luteinizing hormone (LH) and Follicle stimulating hormone (FSH). Follicle stimulating hormone principally stimulates the production of spermatogonia to spermatocytes and also maintains the spermatogenic process. Both follicle stimulating hormone and Luteinizing hormone are necessary for meiosis and development of spermatids. Testosterone has been found to be the main male gonadal hormone produced by the interstitial cells of Leydig of the testis. In addition to LH and FSH, testosterone is the major hormonal marker of androgenicity. It is principally concerned with the growth, development and maintenance of male reproductive organs.<sup>[12]</sup> In association with FSH, testosterone acts on the seminiferous tubules to initiate and maintain spermatogenesis.<sup>[13]</sup>

The statistically significant elevation in the concentration of FSH therefore suggests that the *S.aethiopicum* fruit has a stimulatory action on the hypothalamic-pituitary axis. The pro-gonadotropic action by the extract indicates that it may enhance the normal functioning of the Sertoli cells which will increase sperm cell maturation. The statistically significant elevation in the concentrations of the gonadotropic hormones in all the experimental groups suggests a direct action on the anterior pituitary hormongogenesis.

These findings of this research agree with the studies on the fertility effects of other plant extract (*Allium sativum*) by other researchers who reported that saponins, flavonoids, alkaloids and tannins present in plant extracts have the capability of increasing the body's natural Testosterone, LH and FSH levels.<sup>[13]</sup> Luteinizing hormone which is released by the pituitary gland has been found to help in maintaining testosterone levels.<sup>[14]</sup> This therefore implies that the observed increase in Luteinizing hormone level may be responsible for the increase in testosterone concentration which enhances male fertility.

### Effect of Hydro-ethanolic fruit extract of *S. aethiopicum* on Sperm Parameters

Table 3 reveals the action of the various dosages of the fruit on sperm parameters. It shows that there was a statistically significant elevation in the percentage of sperm viability and motility in most of the experimental groups with respect to the control group. There was also a statistically significant elevation in sperm count in the experimental group with the highest extract dose with respect to the control group while there was no significant change in the percentage of cells with normal morphology with respect to the control. Sperm count, motility, viability and morphology are usually evaluated to determine the fertility of a male subject. The enhancing action of the fruit on sperm characteristics could be attributable to favourable and increased spermatogenic activities in all the experimental groups. Increase in the epididymal sperm count as observed in this study may be associated with testosterone increase.

The testis performs two major functions: Steroidogenesis and spermatogenesis (production of testosterone and maintaining spermatogenesis). It does this through coordination between various cell types, including Sertoli, Leydig and germ cells.<sup>[11]</sup> Testosterone regulates spermatogenesis in males through phosphorylation of cAMP response element-binding protein (CREB) and its increase has been associated with improvement in sperm quantity and quality.<sup>[12]</sup> The statistically significant increase in sperm count in the experimental groups in relation to the control group could be ascribed to the importance of *Solanum aethiopicum* as a potent antioxidant and free radical scavenger.<sup>[13]</sup> This finding corroborates with the work of others which established that potent antioxidants ameliorate increased free radicals generated by both natural and experimental stress, thereby causing a substantial elevation in the spermatogenic activity by increasing the production of testosterone from the Leydig cells.<sup>[14]</sup>

This result also agrees with the finding of the research done by others on the testes of male Wistar rats with mercury chloride induced toxicity treated with *S. melongena* fruits.<sup>[15]</sup>

Luteinizing hormone reportedly induces testosterone secretion from the interstitial cells of Leydig of the testes which in turn is also required for the growth and development of male reproductive organs<sup>[16]</sup> and in association with FSH, acts on the seminiferous tubules to initiate and maintain spermatogenesis.<sup>[17]</sup>

This finding of this research therefore indicates that *S. aethiopicum* is capable of increasing serum levels of testosterone and further suggest that it could have a positive impact on testicular androgen secretory function which promotes maintenance of spermatogenesis.

## Effect of administration of Hydro-ethanolic fruit extract of *S. aethiopicum* on the Histology of the Testes

The histology of the testes in all the experimental groups after 30 days of extract administration revealed a normal histology in comparison with the control. This suggests that the fruit extract of *S. aethiopicum* may have a protective effect on the testis thereby promoting fertility. This protective effect on the testis may be attributed to the presence of flavonoid in the fruit extract which has been found to possess cyto-protective activities. It has also been found that flavonoids are effective in the prevention of lesion and in the scavenging of free radicals, generated by natural and experimental stress that may damage testicular cell structure<sup>[18]</sup>

## CONCLUSION

The study showed that the hydroethanolic fruit extract of *Solanum aethiopicum* caused a significant dose dependent increase in the serum concentration of male reproductive hormones (FSH, LH and Testosterone) such as Follicle stimulating hormones, luteinizing hormone and Testosterone. There was also a significant elevation in the percentage sperm motility and percentage of viable sperm cells in relation to the control. It was also found to be capable of protecting or preserving the cytoarchitecture of the testis. These results show that the continuous intake or consumption of the fruit of *Solanum aethiopicum* (garden egg) may increase the concentration of reproduction hormones and cause an appreciable improvement in sperm parameters in male wistar rats and therefore capable of boosting their reproductive potential.

## COMPETING INTERESTS

No competing interests exist.

## AUTHOR'S CONTRIBUTIONS

Author Zabbey VZ conceived the study, designed the protocol and contributed in writing the manuscript, authors Adienbo OM and Dapper DV coordinated the experiment, performed the laboratory procedures and contributed in writing the manuscript while author Ojeka SO performed the statistical analysis, data interpretation and also contributed in the manuscript writing. The authors have all read through and approved the final manuscript.

## ACKNOWLEDGEMENTS

The authors would like to express warm appreciation to Dr Suleiman from the Department of Pharmacognosy and Phytotherapy, Faculty of Pharmaceutical Sciences, University of Port Harcourt, for his contribution in the identification and authentication of the plant.

## REFERENCES

1. Sachin J, Gajendra PC, Dinesh KJ. (2015). Medicinal plants with potential anti-fertility activity: A review. *International Journal of Green Pharmacy*,9(4): 223-228.
2. Eric RM, Jauniaux, Botros Rizk RM (2012). *Pregnancy After Assisted Reproductive echnology*. (Cambridge University Press), UK, 1-3.
3. Mukherjee PW. (2002). *Quality Control of Herbal Drugs: An Approach to Evaluation of Botanicals*. New Delhi, India, Elesvier, 784.
4. Nejatbakhsh F, Shirbeigi L, Rahimi R, Abolhassani H. (2016). Review of local herbal compounds found in the Iranian traditional medicine known to optimise male fertility. *Andrologia*. 48(8): 850-859.
5. Subramoniam A, Madhavachandran V, Rajasekharan S, Pushpangadan A (1997). Aphrodisiac properties of *Trichopus zeylanicus* extract in male mice. *J Ethnopharmacol*, 157: 21-27.
6. Kumar SKP, Subramoniam A, Pushpangadan P (2000). Aphrodisiac activity of *Vanda tessellate* (roxb.) Hook. Ex don extract in male mice. *Indian J Pharmacology*, 232: 300-304.
7. Zheng BL, He K, Kim CH (2000). Effect of a lipidic extract from *Lepidium meyenii* on sexual behavior in mice and rats. *Urology*, 55: 598-602.
8. Arletti R, Benelli A, Cavazzuti E (1999). Stimulating property of *Turnera diffusa* and *Pfaffia paniculata* extracts on the sexual behaviour of male rats. *Psychopharmacology*, 143: 15-19.
9. Xu X, Yin H, Tang D (2003). Application of traditional Chinese medicine in the treatment of infertility. *Human Fertility*, 6: 161-168.
10. Osunga IO, Ezinma EN, Adenowo TK, Adelegam AA (2020). Effect of aqueous extract of *Allium sativum* (Garlic) on fertility in male Wistar rats. *Annals of Hel. Res*, 6(1).
11. Fouad, A.A., Jresat, I. (2015). Thymoquinone therapy abrogates toxic effect of cadmium on rat testes. *Andrologia*. 47:417-26.
12. Walker, W.H. (2009). Molecular mechanisms of testosterone action in spermeogenesis. *Steroid*. 74:602-7.
13. Tafuri S, Ciani F, Lori EL, Esposito L, Cocchia N. (2015). Reactive oxygen species (ROS) and male



- fertility. In *New Discoverie in Embryology*. Bin Wu: InTech
14. Saalu, L.C, Oluyemi, K.A. and Omotuyi, I.O. (2007a)  $\alpha$ -Tocopherol (vitamin E) attenuates the testicular toxicity associated with experimental cryptorchidism in rats. *African Journal of Biotechnology*, 6 (12): 1373-1377.
  15. Adelokun, S.A., Ukwanya, O.V., Akingbade, G.T., Olusegun Dare Omotoso, Aniah, J.A. (2019). Interventions of aqueous extract of *Solanum melongena* fruits (garden eggs) on mercury chloride induced testicular toxicity in adult male Wistar rats. *Biomedical Journal* 43:174-182.
  16. Mooradian, A.D., Morley, J.E. and Korenman, S.G. (1987). Biological actions of androgens. *Endocrine*, 8: 1-27.
  17. Christensen, A.K. (1975). Leydig cells. In: Hamilton D.W., Greep RO (eds) *Handbook of Physiology*, vol. 5. American Physiological Society, Washington, pp 57-94.
  18. Elujoba, A. A., Odeleye O. M. and Ogunyemi, C. M. (2005). Traditional medical development for medical and dental primary healthcare delivery system in Africa. *African Traditional Complementary and Alternative Medicine* 2(1): 41-46.

**Cite this Article:** Zabbey VZ; Adienbo OM; Ojeka SO; Dapper DV (2021). Evaluation of the Hydroethanolic Fruit Extract of *Solanum aethiopicum* (Garden Egg) on the Concentration of Reproductive Hormones, Sperm Parameters and Histology of the Testis of Male Wistar Rats. *Greener Journal of Medical Sciences*, 11(2): 249-256.